

Oral Medicine FULL Referral Guide (FRG)

Yorkshire & the Humber

February 2017

Contents

Introduction.....	1
Oral Medicine Referral – Decision Process.....	1
Step 1. Oral Medicine Condition?.....	2
A. Soft Tissues.....	3
B. Salivary Glands.....	4
C. Pain & Neurological Dysfunction.....	5
Step 2. Consider if Oral Cancer May be Present.....	5
Step 3. Initial Assessment of the Level of Care Required.....	6
Step 4. Care Provider Preference.....	7
Step 5. Urgency of Referral.....	7
Improving this Guide.....	8
Advice.....	8

Appendices

Appendix 1	Oral Medicine referral form (for e-RMS registered dental team).....	9
Appendix 2	Examples to inform referral decision-making.....	10
	A. Oral Soft Tissue Presentations.....	10
	B. Salivary Gland Presentations.....	15
	C. Pain & Neurological Dysfunction Presentations.....	16
Appendix 3	Suspected Cancer.....	18

Introduction

The Oral Medicine Full Referral Guide (FRG) should be used to inform referrals from primary care to L2 and L3 care providers. Referrals should be made via an electronic system.

'Dental Referrals' - Dental Team in Primary Care:

- For referrals from the primary care dental team use the **electronic-Referral Management System** (e-RMS). Detailed information can be found in the 'West Yorkshire Oral Surgery and Oral Medicine Service Referral Handbook' available via the 'Referral Guidance Document' link in the e-RMS website - <https://www.dental-referrals.org/>
- A copy of the 'Oral Medicine' referral form is included in Appendix 1 for your information. This form is available 'online'.

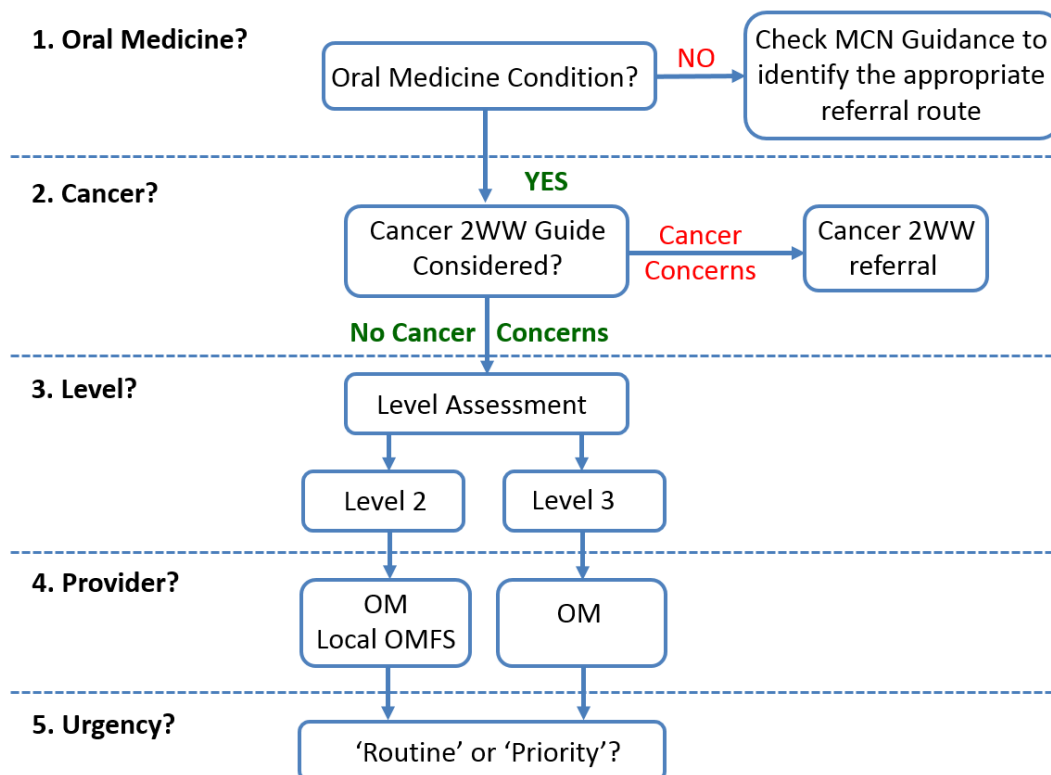
'NHS e-Referral Service' – Other Healthcare Professionals in Primary Care

Referral should be made via the 'NHS e-Referral Service'.

This guide is designed to help **ALL referrers** considering a referral of a patient that falls within the scope of Oral Medicine practice.

Oral Medicine Referral – Decision Process

Where there may be an Oral Medicine (OM) condition and referral is being considered, there is a 5-step process to follow.



Abbreviations: OM (Oral Medicine – in Leeds and Sheffield); OMFS (Oral & Maxillofacial Surgery); 2WW (2 Week Wait).

For a brief overview, look at the **Oral Medicine Quick Referral Guide (QRG)**.

Step 1. Oral Medicine Condition?

Is the patient's problem within the scope of Oral Medicine clinical practice?

Oral Medicine is the specialty of dentistry concerned with the care of adults and children with chronic, recurrent and medically related disorders of the oral and maxillofacial region, and with their diagnosis and non-surgical management.

The key difference from Oral Surgery and Oral & Maxillofacial Surgery is that in Oral Medicine the emphasis is on conditions that are primarily managed medically without the need for surgery.

The scope of Oral Medicine practice primarily includes disorders of:

- A. Oral soft tissues (including the lips)**
- B. Salivary glands**
- C. Pain & Neurological dysfunction including non-dental-related pain**

Oral Medicine disorders may reflect:

- Local oral problems **or**
- Oral manifestations of systemic problems (e.g. gastrointestinal, rheumatological, dermatological, haematological, autoimmune, psychiatric or psychological disorders).
 - As part of the referral process this category can be marked as '**Oral presentation of a wider problem**'.

Oral Medicine acts as a focus for specialist interdisciplinary care of patients and there is close collaboration with other dental, medical and surgical specialties as required.

Many conditions that fall within the scope of Oral Medicine practice are chronic and may have a significant psychological, as well as physical impact on the patient's quality of life.

Further information about Oral Medicine can be found at: www.bsom.org.uk

A. Oral Soft Tissues

Features of oral soft tissue presentations include:

- Symptoms - awareness of changes (e.g. altered sensations, discomfort, pain, swelling, altered function) or changes causing worry.
- Visible changes on examination.
- Incidental findings.

Clinical signs/symptoms:- <i>include</i>	Example diagnoses:- <i>include</i>
Ulceration – recurrent or persistent	Recurrent aphthous stomatitis
Red and/or white lesions – focal or widespread	Lichen planus & lichenoid reactions (dental restorations or medication)
Pigmented lesions	Graft versus Host Disease (GvHD) ^{L3}
Blisters (fluid filled)	Hyperkeratosis (no specific diagnosis made on biopsy)
Focal swellings	Pemphigoid ^{L3}
Full thickness soft tissue swelling	Pemphigus ^{L3}
Fibrosis	Erythema multiforme ^{L3}
Angular cheilitis	Infections (viral, fungal or bacterial)
	Behçet's disease ^{L3}
	Angioedema ^{L3}
	Orofacial granulomatosis & oral Crohn's disease ^{L3}
	Oral submucous fibrosis ^{L3}
	Polyp and epulis

L3 – Level 3 assessment indicated.

Ulcer	break in the lining of or loss of epithelium of the mucous membrane
Erosion	superficial damage to/loss of epithelium
Atrophy	thinning of epithelium
Plaque	circumscribed raised area mostly >20mm in diameter (usually white)
Macule	flat, circumscribed area of mucosa (typically pigmented)
Papule	circumscribed raised lesion <5mm diameter
Nodule	circumscribed raised lesion >5mm diameter
Bulla	blister* (fluid filled swelling) > 5mm diameter involving mucosa or skin
Vesicle	blister* (fluid filled swelling) <5mm diameter involving mucosa or skin
Cyst	sac-like cavity containing fluid that may arise from a minor salivary gland or other submucosal structure (compare: 'vesicle' and 'bulla')

* Note: Some patients may mention 'blisters' when they are referring to 'ulcers'. Check if the lesions experienced include fluid (e.g. like a skin blister when a shoe rubs on the skin).

Desquamative gingivitis: Clinical description (NOT a diagnosis) of an inflamed erythematous (red), desquamated (shedding) appearance to the attached gingivae (often full thickness) most commonly seen in mucocutaneous conditions affecting the mouth.

See Appendix 2 for example presentations & related guidance

Salivary Glands

Features of salivary gland presentations include:

- Symptoms – awareness of changes (e.g. dryness, wetness, altered saliva properties), discomfort, pain, or causing worry.
- Visible changes on examination – can be difficult with saliva quantity.
- Incidental finding.

Clinical signs/symptoms:- include	Example diagnoses:- include
Oral dryness or decreased saliva volumes	Sjögren's syndrome ^{L3}
Excessive oral wetness or increased saliva volume	Iatrogenic (medication)
Salivary gland swelling (minor or major salivary glands)	Problems secondary to other illness ^{L3}
	Sialorrhoea (excess of saliva) ^{L3}
	Sialosis
	Mucocele

L3 – Level 3 assessment indicated.

See Appendix 2 for example presentations & related guidance.

B. Pain & Neurological Dysfunction

Features of pain and neurological dysfunction presentations include:

- Symptoms – awareness of changes (e.g. discomfort, pain, altered sensations, altered function) or causing worry.
- Visible changes on examination.
- Coincidental finding.

Clinical signs:- <i>include</i>	Example diagnoses:- <i>include</i>
Altered sensations when the mouth looks normal, such as: <ul style="list-style-type: none"> • Burning or stinging • Sensation of dryness with moist mouth • Abnormal taste that improves with chewing 	Oral dysaesthesias including Burning Mouth
Symptoms and signs related to the: <ul style="list-style-type: none"> • Temporomandibular joints • Muscles of mastication 	Temporomandibular joint dysfunction including myofascial pain
Other orofacial pain that is NOT due to dental disease (e.g. caries or periodontal disease) i.e. where dental pain has been excluded by a dentist	Persistent idiopathic facial pain (atypical facial pain)
Numbness: ^{L3} <ul style="list-style-type: none"> • Partial or complete • Comes & goes or permanent 	Atypical odontalgia
Other cranial nerve dysfunction including: ^{L3} <ul style="list-style-type: none"> • Facial nerve palsy 	Trigeminal neuralgia ^{L3}
	Giant cell arteritis ^{L3}

L3 – Level 3 assessment indicated.

See Appendix 2 for example presentations & related guidance.

Step 2. Consider if Oral Cancer May be Present.

ALWAYS consider if the presentation may represent mouth cancer.

For conditions that fall within the scope of Oral Medicine practice, always consider if the presentation represents cancer.

Where cancer is suspected, then referral should be made via the local urgent “Fast-Track” 2 week cancer service and NOT via the Oral Medicine Referral Form.

See Appendix 3 for further guidance.

Step 3. Initial Assessment of the Level of Care Required

When referring from primary care for an Oral Medicine condition:

- **Assume that the complexity level is Level 2 unless there is a clear indication for Level 3 care, in which case this should be explicit in the referral.**

The complexity levels for conditions that fall within the scope of Oral Medicine practice are.

Level 1

Level 1 care involves:

- Recognition of normal features of the mouth and oropharynx that may be confused with pathology.
- Recognition of conditions and recording an initial (working) diagnosis.
- Initiation of management (e.g. identify & address concerns, appropriate information, interventions including oral hygiene and 1st line topical treatments) with appropriate follow-up.
- Recognition of situations where the presenting complaint indicates referral to either Level 2 or 3.
- Ongoing management as part of shared care or following discharge from Level 2 or 3 care.

Level 2

Level 2 care involves:

- Re-evaluation of the initial diagnosis and the aims of care.
- Re-evaluation and revision of management with follow-up.
- Recognition of situations where the presenting complaint indicates referral for Level 3 assessment.
- Ongoing management as part of shared care with Level 1 or 3 care.

Level 3

Level 3 care involves:

- Evaluation of presentations associated with prominent or unusual orofacial symptoms and/or signs (mucosal, salivary, pain or neurological).
- Evaluation of presentations that may represent an orofacial manifestation of a systemic or widespread problem with physical and / or psychological components.
- Re-evaluation where the diagnosis is unclear.
- Management is complicated by significant co-morbid illness (physical or mental health) or the management of this.
- Interventions at Level 2 have not achieved a satisfactory outcome.
- Management requires potent topical or systemic medications.
- Multi-disciplinary or multi-professional management is indicated.

See Appendix 2 for example presentations & related guidance.

Step 4. Care Provider Preference

In the referral make a preference for the centre to provide the initial assessment.

Leeds Dental Institute Oral Medicine (LDI OM)

- The regional NHS specialist Oral Medicine services are provided in:
 - Leeds Dental Institute.
 - Charles Clifford Dental Hospital, Sheffield.
- The main providers of Oral Medicine education and training in the region.
- Accept Level 2 referrals.
- The preferred centres for Level 3 care.

Local Oral & Maxillofacial Surgery (OMFS) Units

- Providers of NHS Oral Medicine care close to where patients are.

It is important to note that the preference made is for the initial assessment and ongoing care may involve:

- A different provider.
- Shared care between different providers.

See Appendix 2 for example presentations & related guidance.

Step 5. Urgency of Referral

In the referral make a preference for urgency – ‘routine’ or ‘priority’.

When referring from primary care for an Oral Medicine condition:

Routine:

Assume that the urgency is ‘routine’ unless there is a clear indication for a ‘priority’ appointment.

Priority (Urgent):

A request for a ‘Priority’ (urgent) appointment should be considered if:

- The presentation is causing severe distress to the patient.
- There is suspicion of a diagnosis that is likely to require early systemic medication – examples include:
 - Immunosuppression for mucosal disease or full thickness soft tissue swelling.
 - Anti-microbials for infection – e.g. viral or fungal.
 - Pain control – e.g. trigeminal neuralgia.

In the referral it should be clear:

- That a ‘priority’ appointment is requested.
- Why a ‘priority’ appointment is requested.

Note: At triage the accepting clinician may assign a different level of urgency to that requested by the referrer.

See Appendix 2 for example presentations & related guidance.

Improving this Guide:

If you have ideas on how to improve this Referral Guide, then please get in touch via:
alanmighell@nhs.net

Advice:

Advice on patient referral for a patient whose care falls within the scope of Oral Medicine practice can be accessed via:




- Leeds (0113) 3434583.
- Sheffield (0114) 2717800




Messages can be left, so please speak clearly if leaving contact details for a return call.



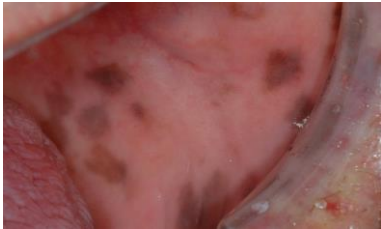

APPENDIX 2 – Examples to inform referral decision-making

- The information in this appendix is designed to help decision-making and referral.
- It is not comprehensive and does not cover all possibilities.


A. Oral Soft Tissue Presentations


<i>Recurrent Oral Ulceration e.g. aphthous ulcers:</i>	<i>Typical oral presentation</i>	<i>Red Flags: Level 3 Referral</i>
	<p>Repeated episodes of self-limiting ulceration:</p> <ul style="list-style-type: none"> - Labial, buccal or ventral tongue - Oval shape - Size <10mm - Resolve <14 days - Sites of ulcers vary - Mucosa normal once ulcers heal 	<p>Features that do not fit the typical oral presentation</p> <p>Unexplained other features such as:</p> <ul style="list-style-type: none"> - systemic upset - gastrointestinal problems - fevers - genital ulceration - joint problems - skin rashes - eye soreness or redness
<i>Acute onset painful ulcers: Viral</i>	<i>Typical oral presentation</i>	<i>Red Flags: Level 3 Referral</i>
	<p>Acute onset small ulcers:</p> <ul style="list-style-type: none"> - Multiple ulcers in most - Marked erythema around ulcers to start with - Resolve <14 days - Cervical lymphadenopathy - Fever - Malaise - Childhood 	<p>Features that do not fit the typical oral presentation</p> <p>Present in adulthood</p>
<i>Persistent Superficial Ulceration:</i>	<i>Typical oral presentation</i>	<i>Red Flags: Level 3 Referral</i>
	<p>Persistent, superficial ulceration:</p> <ul style="list-style-type: none"> - Often multiple sites - Ulcers are shallow and surrounded by inflammation - Size - variable (can be several centimetres) - Soft on palpation - Persist for weeks or months without settling - Can be associated scarring 	<p>Typical oral features</p> <p>Features that do not fit the typical oral presentation</p> <p>Unexplained other features such as:</p> <ul style="list-style-type: none"> - systemic upset - eye soreness or redness - genital ulceration - nasal soreness - skin rashes


Desquamative Gingivitis:	Typical oral presentation	Red Flags: Level 3 Referral
	<p>Bright band of redness of the attached gingivae that:</p> <ul style="list-style-type: none"> - Cannot be attributed to dental plaque. - May be generalised or localised. - May be diffuse & patchy or well-defined. - May be associated with superficial ulceration. - May occur with other oral mucosal lesions. - Persists for weeks or months without settling. 	<ul style="list-style-type: none"> - Features that do not fit the typical oral presentation - Unexplained other features such as: <ul style="list-style-type: none"> - systemic upset - eye soreness or redness - genital ulceration - nasal soreness - skin rashes
Redness where shaggy whiteness rubs off:	Typical oral presentation	Red Flags: Level 3 Referral
	<p>Redness with white shaggy areas:</p> <ul style="list-style-type: none"> - May be generalised or localised. - May be diffuse & patchy or well-defined. - Whiteness can be rubbed away to leave a bright red base - associated with superficial ulceration. - Worst at sites of trauma. - Persists for weeks or months without settling. 	<ul style="list-style-type: none"> - Typical oral features – pemphigus needs to be excluded. - Features that do not fit the typical oral presentation - Unexplained other features such as: <ul style="list-style-type: none"> - eye soreness or redness - genital ulceration - nasal soreness - skin rashes
Persistent White and/or Red Mucosal Lesions:	Typical oral presentation	Red Flags: Level 3 Referral
	<ul style="list-style-type: none"> - Reticulated or plaque-like hyperkeratosis with variable redness and/or ulceration (may be none). - Symmetrical involvement of the posterior buccal mucosa is common, but any site may be involved. - Desquamative gingivitis can be present. - Lesions may be unilateral/adjacent to dental restorative materials 	<ul style="list-style-type: none"> - Features that do not fit the typical oral presentation - Unexplained other features such as: <ul style="list-style-type: none"> - skin rash - nail changes - genital ulceration - scalp soreness or acute hair loss - Widespread oral involvement <p><i>Note: cancer development in oral lichen planus is <1 in 100 who have oral lichen planus for 10 years or more.</i></p>


<i>Persistent White Patch:</i>	<i>Typical oral presentation</i>	<i>Red Flags: Level 3 Referral</i>
	<ul style="list-style-type: none"> - Plaque-like hyperkeratosis with minimal or no redness and/or ulceration (may be none). - Lesions may be unilateral/adjacent to dental restorative materials (as here). 	<ul style="list-style-type: none"> - Features that do not fit the typical oral presentation. - Widespread oral involvement.
<i>Crusted lip lesions:</i>	<i>Typical oral presentation</i>	<i>Red Flags: Level 3 Referral</i>
	<ul style="list-style-type: none"> - Crusted lesions on the external lips. - Sudden onset. - May be associated with oral lesions (including ulceration). - Lesions settle within 2 weeks. - Some experience repeated attacks. 	<ul style="list-style-type: none"> - Typical oral features. - Features that do not fit the typical presentation. - Unexplained other features such as: <ul style="list-style-type: none"> - eye soreness or redness - genital ulceration - nasal soreness - skin rashes - Note: single site persistent ulceration – consider Appendix 3
<i>Brown Pigmented Lesions:</i>	<i>Typical oral presentation</i>	<i>Red Flags: Level 3 Referral</i>
	<p>Brown-pigmented lesion(s)</p> <ul style="list-style-type: none"> - Single or multiple. - Can be ill-defined. - Flat and not raised. - Soft and not indurated. <p>Note: diffuse oral mucosal pigmentation is a normal feature in those with dark skin.</p>	<ul style="list-style-type: none"> - Features that do not fit the typical oral presentation. - Widespread oral involvement. - Unexplained other features.
<i>Blue-Black Pigmented Lesions:</i>	<i>Typical oral presentation</i>	<i>Red Flags: Level 3 Referral</i>
	<ul style="list-style-type: none"> - Blue-black-pigmented lesion(s) - Single or multiple. - Can be ill-defined. - Flat and not raised. - Soft and not indurated (i.e. not firm or hard). 	<ul style="list-style-type: none"> - Features that do not fit the typical oral presentation. - Widespread oral involvement. - Unexplained other features.

Focal soft tissue lumps and bumps:


Fibroepithelial Polyp:	Typical oral presentation	Red Flags: Level 3 Referral
 <p><i>Note: traumatic hyperkeratosis also present along the occlusal line in the lower image.</i></p>	<p>Slow growing soft tissue lump</p> <ul style="list-style-type: none"> - Typically on lips, buccal mucosae, tongue at sites exposed to frictional forces e.g. repeated biting. - Overlying mucosa looks normal, unless traumatised. - Sessile (broad-base) or pedunculated (on a stalk). - Painless unless traumatised. - Soft and not indurated. - Do not resolve spontaneously. 	<p>Features that do not fit the typical oral presentation.</p>


Epulis:	Typical oral presentation	Red Flags: Level 3 Referral
	<p>Soft tissue lump:</p> <ul style="list-style-type: none"> - Arising from gingival margin. - Mostly slow-growing – ('pregnancy epulis' can grow quickly). - Colour variable – normal mucosa, red or blue/purple - Overlying mucosa looks normal, unless traumatised (as on left side of the lesion illustrated). - Sessile (broad-base) or pedunculated (on a stalk). - Painless unless traumatised. - Soft and not indurated. - Teeth not mobile. - Do not resolve spontaneously (although the 'pregnancy epulis' can settle after delivery). 	<ul style="list-style-type: none"> - Features that do not fit the typical oral presentation. - Associated focal bone loss on periapical radiography.

Mucocoele:	Typical oral presentation	Red Flags: Level 3 Referral
	<p>Soft tissue swelling:</p> <ul style="list-style-type: none"> - Lower lip mostly - Rapid size increase (hours/days) - Domed – broad base (not pedunculated) - Can spontaneously resolve (to a scar) or swell & shrink repeatedly (may exude fluid) - Fluctuates when fluid-filled. - Soft and not indurated, although on resolution a submucosal scar may be palpable. - Transilluminates when fluid-filled (image inset). 	<ul style="list-style-type: none"> - Features that do not fit the typical oral presentation. - Upper lip - minor salivary gland neoplasia possible.


Wart:	Typical oral presentation	Red Flags: Level 3 Referral
	<p>Focal soft tissue swelling:</p> <ul style="list-style-type: none"> - Warty, irregular surface - Pedunculated (on a stalk) or broad base - May affect any intraoral site including soft palate and oropharynx <p>May have warts elsewhere e.g. hands or genitals</p>	<ul style="list-style-type: none"> - Features that do not fit the typical oral presentation. - Other unexplained oral features.


Full Thickness Soft Tissue Swelling:

Persistent Orofacial Swelling:	Typical oral presentation	Red Flags: Level 3 Referral
	<ul style="list-style-type: none"> - Swelling of the orofacial soft tissues – bottom lip here. - Unilateral or bilateral - variable symmetry. - Initially may come and go, before becoming persistent. - May be associated with angular cheilitis and/or lip fissures. - May be associated with oral changes – e.g. ulceration, erythema & soft tissue tags. 	<ul style="list-style-type: none"> - Typical oral features - Features that do not fit the typical oral presentation. - Unexplained other features such as: <ul style="list-style-type: none"> - Malaise - Gastrointestinal symptoms.

Sudden Onset Orofacial Swelling:	Typical oral presentation	Red Flags: Level 3 Referral
	<ul style="list-style-type: none"> - Swelling of the orofacial soft tissues – left lower face in this case. - Lesions may be unilateral or bilateral with variable symmetry. - Onset rapid (minutes/hours). - Settles over days. - Repeated attacks. 	<ul style="list-style-type: none"> - Typical oral features - Features that do not fit the typical oral presentation. - Unexplained other features.

Salivary Gland Presentations

Oral Dryness (Xerostomia)	Typical presentation	Red Flags: Level 3 Referral
	<p>Dry mouth (although not always as dry as the case illustrated) that may be associated with:</p> <ul style="list-style-type: none"> - Difficulty chewing and swallowing dry foods. - Recurrent/persistent oral infections e.g. oral <i>Candida</i>. - Bad breath or altered taste. - Dental decay or periodontal disease. - Difficulties with dentures. - Persistent dryness of the mouth +/- eyes and other mucosal sites. 	<ul style="list-style-type: none"> - Typical oral features (wide differential diagnosis) unless mild - Features that do not fit the typical oral presentation. - Other unexplained oral features. - Unexplained other features such as: <ul style="list-style-type: none"> - Dry eyes. - Dry nose. - Dryness of other mucosal surfaces. - Arthritis. - Fatigue. - Ill-defined illness.

Salivary Gland Enlargement	Typical presentation	Red Flags: Level 3 Referral
	<p>Enlarged major salivary glands:</p> <ul style="list-style-type: none"> - Gradual onset. - Not fluctuating in size. - Symmetrical (parotid & submandibular glands). - Painless. - Soft. - Mouth is moist. 	<p>Features that do not fit the typical oral presentation.</p>

Orofacial Pain Presentations

Oral Dysaesthesia:

Typical presentation	Red Flags: Level 3 Referral
Altered sensations when the mouth looks normal, such as: <ul style="list-style-type: none"> - Burning or stinging - Sensation of dryness with a moist mouth - Abnormal taste that improves with chewing 	<ul style="list-style-type: none"> - Features that do not fit the typical oral presentation. - Other unexplained oral or facial features that might include changes to other senses. - Other unexplained features beyond the head and neck.

Temporomandibular Joints and Muscles of Mastication:

Typical presentation	Red Flags: Level 3 Referral
Features may include: <ul style="list-style-type: none"> - Temporomandibular joints: <ul style="list-style-type: none"> - Pain/discomfort - Clicks or crepitations - Restrictions of movement including trismus - Locking (open or closed) - Deviation on opening - Muscles of mastication: <ul style="list-style-type: none"> - Pain/discomfort 	<ul style="list-style-type: none"> - Features that do not fit the typical presentation. - Features listed in Appendix 2 – ‘Trismus’

Trigeminal Neuralgia:

Typical presentation	Red Flags: Level 3 Referral
International Headache Society: <ol style="list-style-type: none"> A. Paroxysmal attacks of pain lasting from a fraction of a second to 2 minutes, affecting one or more divisions of the trigeminal nerve and fulfilling criteria B and C. B. Pain has at least one of the following characteristics: <ul style="list-style-type: none"> - Intense, sharp, superficial, or stabbing. - Precipitated from trigger areas or by trigger factors. C. Attacks are stereotyped in the individual patient. D. There is no clinically evident neurological deficit. E. Not attributed to another disorder*. 	<ul style="list-style-type: none"> - Features that fit the typical presentation. - Features that do not fit the typical presentation.

* exclude dental causes

Other Orofacial Pain:

Typical presentation	Red Flags: Level 3 Referral
Features variable, but may include: <ul style="list-style-type: none"> - Poorly localised aching and/or throbbing that may involve: <ul style="list-style-type: none"> - Deep tissues such as bone (jaws or facial) - Teeth. - Soft tissues. - No dental cause. 	<ul style="list-style-type: none"> - Features that do not fit the typical presentation. - Pain worsened by orofacial muscular activity (e.g. tongue movement or chewing), especially if any of the following are present (urgent care required – exclude Giant Cell Arteritis): <ul style="list-style-type: none"> - Altered vision - Headache - Tender temporal arteries - Jaw pain worsened by general physical activity (e.g. walking) or stress, especially if existing history of heart problems (urgent care required – exclude coronary heart disease)

Numbness:

Typical presentation	Red Flags: Level 3 Referral
Diminished sensation (intraoral and/or facial) that is: <ul style="list-style-type: none"> - Partial or complete - Fluctuating in intensity or unchanged - Worsening over time - Unexplained 	<ul style="list-style-type: none"> - Features that fit the typical presentation. - Features that do not fit the typical presentation.

Other Cranial Nerve Dysfunction (including facial nerve weakness):

Typical presentation	Red Flags: Level 3 Referral
Cranial nerve dysfunction that is: <ul style="list-style-type: none"> - Partial or complete - Fluctuating in severity or unchanged - Worsening over time - Unexplained 	<ul style="list-style-type: none"> - Features that fit the typical presentation. - Features that do not fit the typical presentation. <p>Note: Always consider if there are any features that may indicate <u>urgent medical care</u> – FAST mnemonic for stroke</p> <ul style="list-style-type: none"> - Face – the face may have dropped on one side, the person may not be able to smile or their mouth or eyelid may have drooped. - Arms – the person with suspected stroke may not be able to lift both arms and keep them there because of arm weakness or numbness in one arm. - Speech – their speech may be slurred or garbled, or the person may not be able to talk at all despite appearing to be awake. - Time – it is time to dial 999 immediately if you see any of these signs or symptoms.

APPENDIX 3 – Suspected Cancer

It is important that suspected cancer is referred promptly via the local 2-week-wait (2WW) referral pathway.

It is also important that the 2WW referral pathway is used appropriately.

The **NICE 2015 guidelines** are applicable to all clinicians and not just members of the Dental Team. The need to be inclusive of all clinicians is reflected in the 3 statements on 'Head & Neck Cancers':

- If you are a dentist, then read 1.8.4
- If you are another healthcare professional, then read 1.8.2 and 1.8.3.

1.8.2 Consider a suspected cancer pathway referral (for an appointment within 2 weeks) for oral cancer in people with either:

- unexplained ulceration in the oral cavity lasting for more than 3 weeks or
- a persistent and unexplained lump in the neck. [new 2015]

1.8.3 Consider an urgent referral (for an appointment within 2 weeks) for assessment for possible oral cancer by a dentist in people who have either:

- a lump on the lip or in the oral cavity or
- a red or red and white patch in the oral cavity consistent with erythroplakia or erythroleukoplakia. [new 2015]

1.8.4 Consider a suspected cancer pathway referral by the dentist (for an appointment within 2 weeks) for oral cancer in people when assessed by a dentist as having either:

- a lump on the lip or in the oral cavity consistent with oral cancer or
- a red or red and white patch in the oral cavity consistent with erythroplakia or erythroleukoplakia [new 2015].

Term	Explanation
Erythroplakia	<ul style="list-style-type: none"> • A descriptive term (also referred to as <i>erythroplasia</i>) for a velvety red patch that does not fit with a clinical diagnosis (i.e. which cannot be explained by recent trauma, infection or other oral disease). • High risk for cancer and potentially-malignant states. • Once a histopathological diagnosis has been established, this descriptive term should no longer be used.
Erythroleukoplakia	<ul style="list-style-type: none"> • A descriptive term for a mixed red and white lesion that <ul style="list-style-type: none"> - Cannot be rubbed off with gauze. - Does not fit with a clinical diagnosis (i.e. which cannot be explained by recent trauma, infection or other oral disease). • The lesion may display “speckling” - white areas on a red background. • High risk for cancer and potentially-malignant states. • Once a histopathological diagnosis has been established, this descriptive term should no longer be used.

Term	Explanation
Leukoplakia	<ul style="list-style-type: none"> • This term is not included in the NICE guidance. • A descriptive term for a white patch that: <ul style="list-style-type: none"> - Cannot be rubbed off with a piece of sterile gauze. - Does not fit with a clinical diagnosis (i.e. which cannot be explained by recent trauma or other oral disease). • Low risk for cancer and potentially-malignant states. • Once a histopathological diagnosis has been established, this descriptive term should no longer be used.
Lump consistent with oral cancer	<p>Features include:</p> <ul style="list-style-type: none"> • Swelling arising from the oral soft tissues. • Shape typically irregular and not uniform. • Surface typically irregular and not covered by normal-looking mucosa <ul style="list-style-type: none"> - Inflammation typically present. - Ulceration is common and may be superficial or have rolled borders (raised/heaped-up edges to the ulcer) • On palpation there is induration – a firm feeling that is different from normal soft tissues. • Painless to painful – i.e. variable feature.

Cancer Sites:

- High risk sites for cancer include:
 - Floor of mouth.
 - Ventrolateral tongue (especially posteriorly along with adjacent lingual alveolus - can be difficult to examine).
 - Oropharynx (can be difficult to examine – ‘defensive tongue’).
- Cancer:
 - May involve any part of the oral cavity and oropharynx.
 - May not be immediately obvious:
 - Be systematic in your examination.
 - Inspect and palpate – there may be more to feel than see.

Neck Swelling:

- Neck swelling evident on observation or only by palpation (e.g. lymph node(s), salivary gland or other).
 - Look for any associated neurological dysfunction (e.g. facial nerve weakness).
- Lymph nodes enlargement – look for a cause (e.g. infection, other inflammation or cancer).

Trismus:

- Trismus can be defined as ‘*maximum assisted opening (passive stretch) including vertical incisor overlap of less than 30mm*’.
- Trismus has many causes, but can be associated with cancer.
- Trismus should be considered as a possible presentation of cancer when any of the following are present:
 - Opening <15mm
 - Progressively worsening trismus
 - Absence of a history of TMJ clicking
 - Pain of non-myofascial origin (e.g. neuralgia-like pain)
 - Swollen lymph glands
 - Suspicious intra-oral lesion *OR* an inability to fully examine the oral mucosa

Additional Presenting Features:

In addition to a soft tissue lesion, there may be:

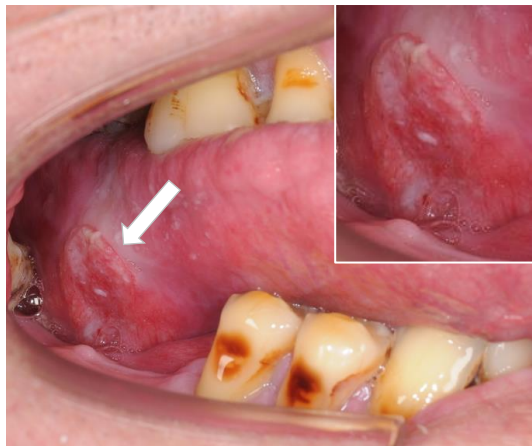
- Unexplained movement of teeth.
- Unexplained altered sensation in the distribution of the trigeminal nerve.
- Unexplained pain in the distribution of the trigeminal nerve.
- Non-healing extraction socket.

Habit-Related Risk Factors - Tobacco, Alcohol and Areca Nut:

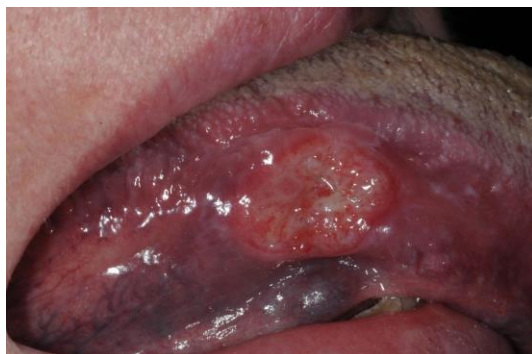- Tobacco and/or alcohol use (current and past) are major risk factors for oropharyngeal cancer that can be asked about.
- Areca nut product use (current and past) - such as paan, quid, masala, gutka - is a major risk factor in South Asian communities where use is cultural.
- Remember, cancer may develop in the absence of any obvious risk factors.

Examples of Cancer Presentations:

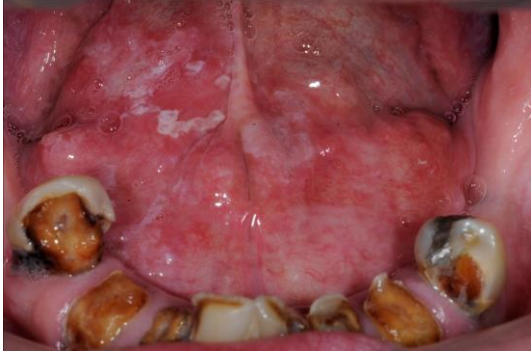Example clinical presentations where cancer should be suspected and referral via the 2 Week Wait (2WW) suspected cancer pathway is indicated.

**Cancer – posterior lateral tongue**

- Single, persistent, shallow ulcer (arrow) - inset: detail of the ulcer.
- Posterior ventrolateral tongue (high risk site).
- Painless or painful.
- Palpate – induration (firmness/hardness) may be present.

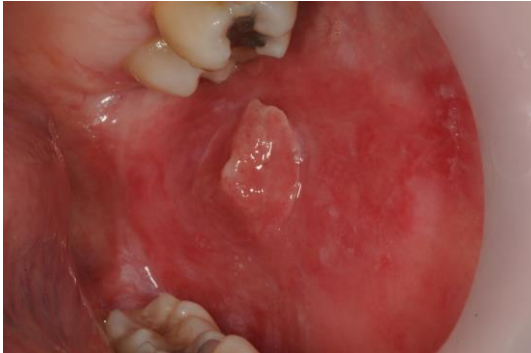**Cancer – posterior lateral tongue**

- Single, persistent ulcerated lump.
- Posterior ventrolateral tongue (high risk site).
- Painless or painful.
- Palpate – induration (firmness/hardness) present beyond the margins of the ulcer.



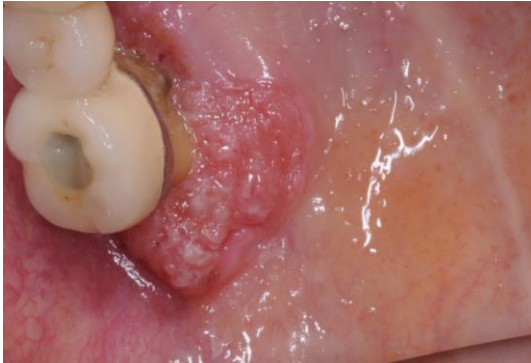Early cancer – floor of mouth

- Erythroleukoplakia.
- Floor of the mouth (high risk site).
- Painless or painful.
- Palpate – induration (firmness/hardness) may be present.



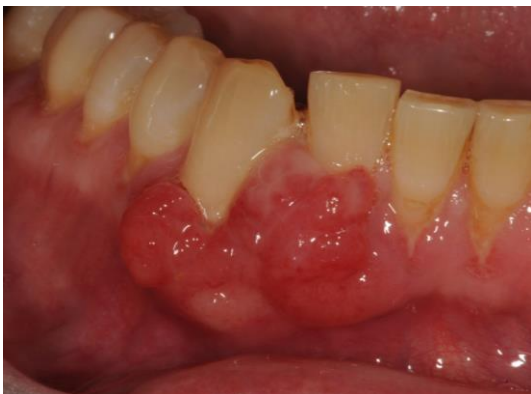Cancer – buccal

- Irregular swelling with surrounding erythroplakia.
- Painless or painful.
- Palpate – swelling induration (firmness/hardness).



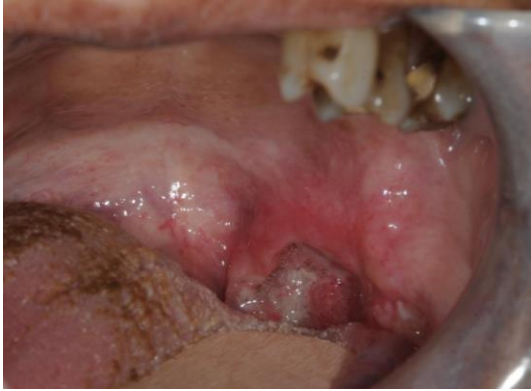Cancer – gingivae

- Gingival lesion with an irregular surface that includes red and white areas.
- Painless or painful.
- Palpate – induration (firmness/hardness) may be present.
- Adjacent molar tooth – may be mobile.
- Periapical radiograph may reveal focal bone loss.



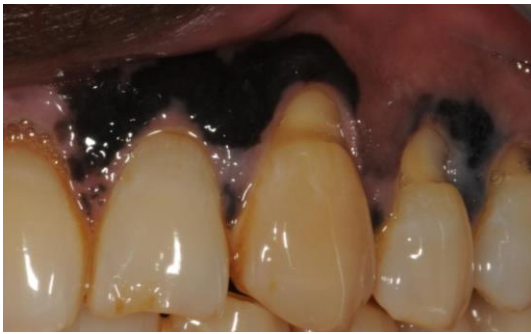Cancer – gingivae

- Irregular soft tissue swelling on the gingivae, but not restricted to the gingival margin.
- Superficial surface ulceration.
- Painless or painful.
- Palpate – induration (firmness/hardness) may be present.
- Teeth may be mobile.
- Periapical radiograph may reveal focal bone loss.



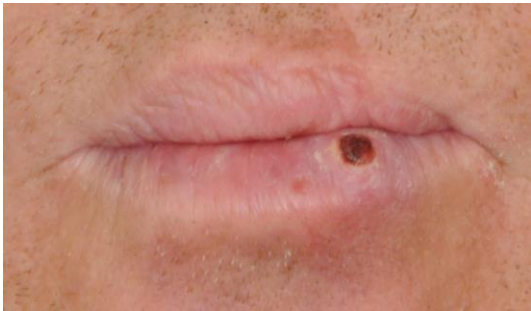Cancer – oropharynx

- Solitary ulcer visible, but only when the ‘defensive’ tongue is physically depressed (a lesion easy to miss).
- Painless or painful.
- Palpate – induration (firmness/hardness) may be present.



Malignant Melanoma

- Rare.
- Typically asymptomatic and flat.
- Worrying features include satellite lesions, colour variations & raised lesions.
- Primary melanoma mostly palate and maxillary gingivae.
- Metastatic melanoma (from primary outside of the mouth) mostly mandible, tongue and buccal mucosa.



- Solitary, persistent lip ulcer.
- Palpate – an indurated lump Palpate – induration (firmness/hardness) evident on palpation of the ulcer.

It is important that suspected cancer is referred promptly via the local 2-week-wait (2WW) referral pathway.

It is important that the 2WW referral pathway is used appropriately - consider the guidance in Appendix 2 of this guide as well.

End